



# ARCEPOCIII

Annual Review of Congresses EN EPOC

Descubriendo lo nuevo en EPOC presentado en ATS, ERS y SEPAR

## ATS - Ics Withdrawal And Treatment With A Fixed-Dose Laba/lama Combination: The German Real-Life Daccord COPD Cohort

Worth H, Buhl R, Criece CP, Kardos P, Lossi NS, Mailander C, Vogelmeier C

# Introducción

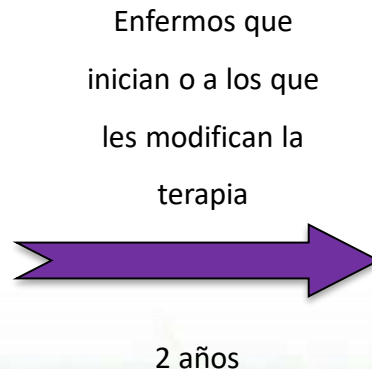
STUDY PROTOCOL

Open Access

## The Prospective Non-Interventional DACCORD Study in the National COPD Registry in Germany: design and methods

Peter Kardos<sup>1\*</sup>, Claus Vogelmeier<sup>2</sup>, Roland Buhl<sup>3</sup>, Carl-Peter Criée<sup>4</sup> and Heinrich Worth<sup>5</sup>

N= 6000  
EPOC (primaria y especializada)



Exacerbaciones  
Función pulmonar  
Adherencia  
Efectos secundarios

Quieren medir las variables de los enfermos que cambiaron Los ICS por doble broncodilatación durante el primer año.

# Métodos

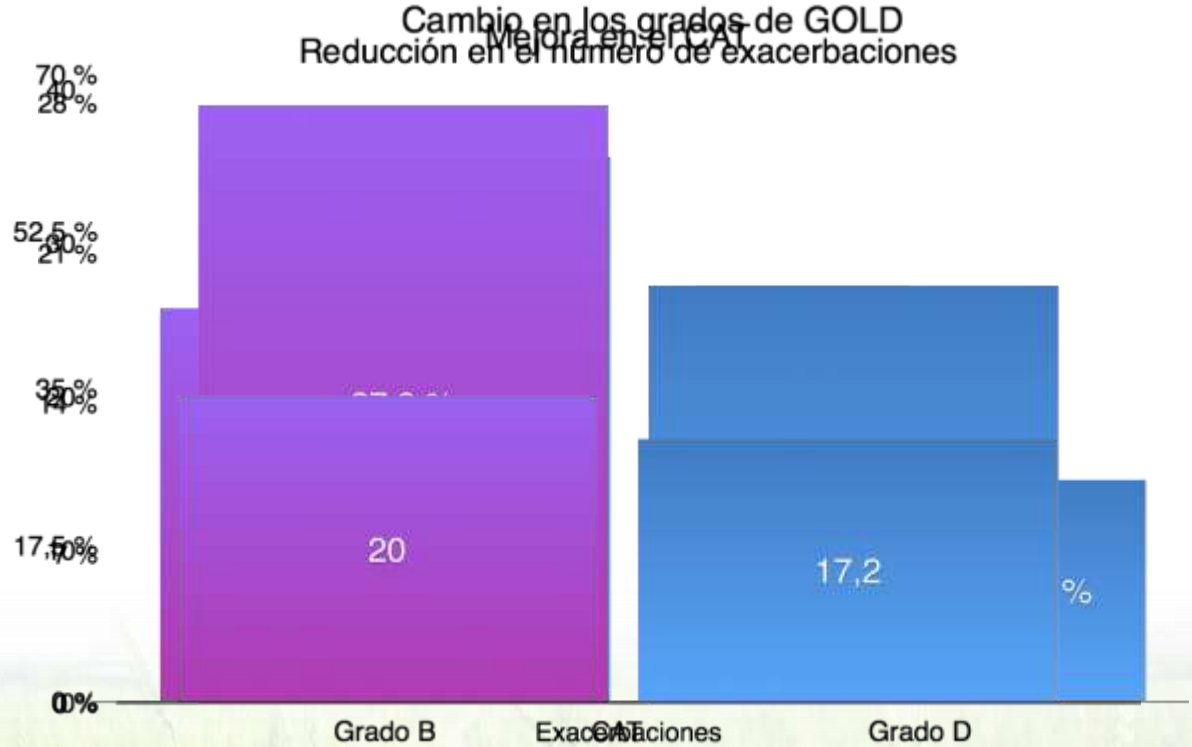
Baseline demographics were collected and COPD severity determined (GOLD 2011). The number of exacerbations was collected over 6 months prior to study entry and every 3 months during the course of the study. Current COPD medication was recorded at each visit. Health status was assessed at baseline and after one year using the COPD Assessment Test (CAT).

# Resultados

N= 766

**ICS Fuera!  
DB Dentro!**

- ICS+LABA= 58%
- Triple= 31%
- ICS= 6,7%
- LAMA+ICS= 2%



## Conclusión

Several recent interventional studies have analyzed the effect of ICS withdrawal in COPD. Here, we extend these findings into a real-life cohort, to show that ICS withdrawal followed by initiation of a LABA/LAMA FDC did not lead to an increase in exacerbations in the following year and was associated with an improvement in health status.

## Discusión

ORIGINAL ARTICLE

### Withdrawal of Inhaled Glucocorticoids and Exacerbations of COPD

Helgo Magnussen, M.D., Bernd Disse, M.D., Ph.D., Roberto Rodriguez-Roisin, M.D.,

ORIGINAL ARTICLE

### Indacaterol–Glycopyrronium versus Salmeterol–Fluticasone for COPD

Jadwiga A. Wedzicha, M.D., Donald Banerji, M.D., Kenneth R. Chapman, M.D.,

## Relapse in FEV<sub>1</sub> Decline After Steroid Withdrawal in COPD CHEST

Lisette I.Z. Kunz MD <sup>a</sup>  , Dirkje S. Postma MD, PhD <sup>c</sup>, Karin Klooster BSc <sup>c</sup>, Thérèse S. Lapperre

The image features the Ferrer logo, which consists of a stylized 'F' icon in teal and green, followed by the word 'ferrer' in a bold, black, lowercase sans-serif font. The logo is centered in the upper half of the frame. The background is a vibrant landscape of a green field with tall grasses in the foreground, extending to a distant horizon under a bright blue sky filled with scattered white clouds. The entire scene is framed by a solid purple border.

**ferrer**